

La 1^{ère} Journée de Rhumato-Gériatrie

Sjögren's syndrome in the elderly

Nouira.H ; Berrihe.O ; Thabet.M ; Arfa.S ; Hammami.S

Internal medicine department, Taher Sfar hospital, Mahdia

Introduction Sjögren's syndrome (SS) is an autoimmune disorder characterized by keratoconjunctivitis sicca and xerostomia resulting from lymphocytic infiltration of the lacrimal and salivary glands.

Objective: to determine the epidemiological, clinical, biological and etiological features of SS in the elderly.

Methods: This is a retrospective study of 14 cases of SS in the elderly (age \geq 65 years) collected in the internal medicine department of Mahdia (Tunisia) during a period from 2011 to 2017. All our patients meet the European criteria.

Results:

*The mean age of patients was 69.4 years (range 65-75 years).

*There is a marked predominance in women (sex ratio=0.16).

*The mean time to diagnosis was 12 months.

***Glandular manifestations** were revealing the disease in 92.8%. The dry syndrome was constant.

***Extra glandular manifestations (figure1)** were frequent (71.4%).

The accessory salivary glands revealed stage III or IV of Chisholm in three cases (21.4%). **The salivary gland scintigraphy** showed an aspect in favor of SS in 2 cases. The anti-SSA and SSB were positive in two cases and the FR in one case. Concerning the etiological diagnosis, the SS was **primitive** in 10 cases (71.4%). It was **secondary** to rheumatoid arthritis in two cases, a systemic lupus erythematosus in one case and autoimmune thyroiditis in one case. The occurrence of a lymphomatous transformation has not been noted.

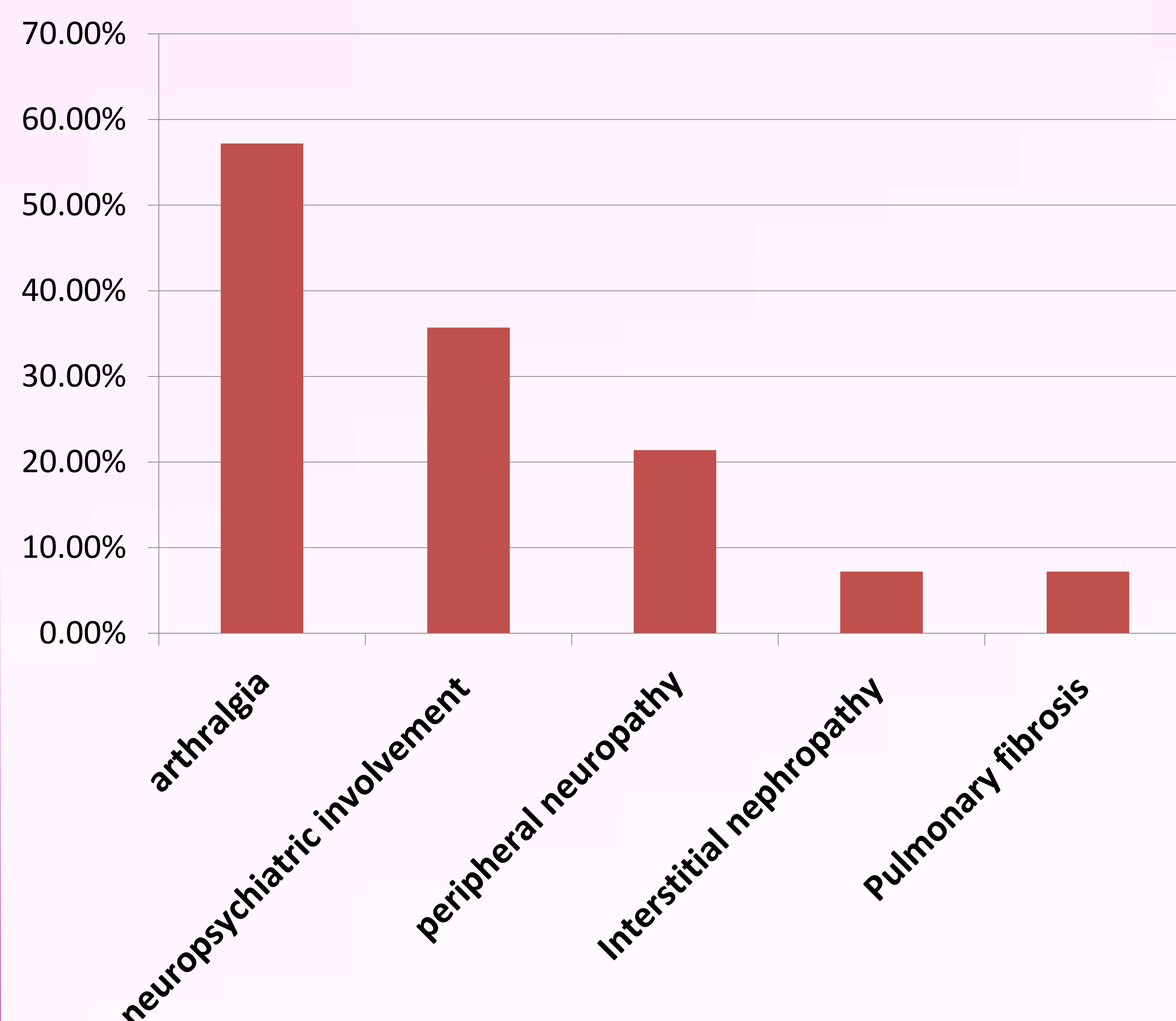


Figure1: Extra glandular manifestations:

Discussion and conclusion:

Diagnosis and treatment of elderly patients with SS is challenging. Our study shows that the extra-glandular manifestations of primary SS are common in elderly. However, the prevalence of immunological abnormalities is low. It can be explained by the senescence of the immune system in this population.

Contrary to the literature, the prognosis in the elderly was not pejorative, no patient in our series presented lymphomatous transformation.

